



Overview of 10 years of practice with CACIPLIQ20[®] matrix therapy as a healing agent for hard to heal wounds: Efficacy, cost-effectiveness and future perspectives

Denis Barritault

OTR3, 4 rue Française, 75001, Paris, France



ARTICLE INFO

Keywords:

Chronic wounds
Matrix therapy
Wound healing
Regenerating agent RGTA
CACIPLIQ[®]20
Wound management

ABSTRACT

Background: Chronic, non-healing wounds remain a major challenge for health care practitioners and for society in general, both in terms of the enormous economic burden on health care systems and the decreased quality of life of the patients.

Objective and methods: To provide the first overview of the use of CACIPLIQ20[®], a matrix therapy agent, over the past 10 years on 4 continents and 15 countries. CACIPLIQ20[®] was used as a last resort for these wounds, which had not shown any evidence of improvement with conventional care and had no expectation of healing. Cases with fully healed wounds were evaluated in order to assess how long complete wound healing can be achieved using this therapy.

Results: Through the evaluation of a selected 119 cases, we found that regardless of wound size or age, treatment with CACIPLIQ20[®] resulted in complete healing (full closure) in about 2 months of a variety of chronic wounds including diabetic foot ulcers, burns, post-amputation/surgical wounds, among others. Moreover, CACIPLIQ20[®] was found to be cost-effective, its current spray format potentially costing 74 euros (64 GBP) to treat wounds measuring an average area of 14 cm² to wound closure. CACIPLIQ20[®] was also widely reported to provide marked pain relief as a consequence of healing.

Conclusions: CACIPLIQ20[®] can heal chronic wounds of various etiologies, sizes and ages in approximately two months, while being cost-effective. By doing so, this treatment can provide major improvement of quality of life through rapid and complete healing of chronic, hard-to-heal wounds and can reduce the economic burden of chronic wounds for health care agencies.

Key messages

Chronic, non-healing wounds remain a major challenge for health care practitioners. We provide the first overview of the use of CACIPLIQ20[®], a matrix therapy agent used for over the past 10 years as a last resort for a variety of non-healing chronic wounds. Complete healing was achieved in 2 months regardless of wound size or age. CACIPLIQ20[®] treatment was found to be cost-effective, potentially costing 74 euros to treat wounds measuring an average area of 14 cm² to wound closure using the current spray format. CACIPLIQ20[®] has been also found to provide pain relief.

1. Introduction

The management of non-healing wounds remains challenging for health care practitioners, costly for health care systems and most

importantly, greatly decreases patient quality of life. Current treatment options available for chronic non-healing wounds include a wide range of dressings, from gauze to tissue engineered skin substitutes, negative pressure wound therapy, growth factors, and hyperbaric oxygen [1]. However, these approaches have seemingly not yet resulted in reducing the rate and quality of chronic wound healing, especially when considering that vast numbers of lower limb amputations are preceded by diabetic foot ulcers [2]. Furthermore, it has become even more crucial to improve chronic wound care management, due to demographic trends and the increasing prevalence of diabetes worldwide [3]. Moreover, in addition to decreasing patient quality of life, wounds present a major burden on health care systems internationally. The cost of treating pressure ulcers alone in the USA has been estimated to approach the \$11 billion/year and the cost of managing DFUs to range between 4–6 billion €/year [4,5].

This overview presents data of a compilation of cases treated with

E-mail address: denis.barritault@otr3.com.

<https://doi.org/10.1016/j.wndm.2020.100180>

Received 7 November 2019; Accepted 31 December 2019

Available online 08 January 2020

2213-9095/ © 2020 The Author. Published by Elsevier GmbH. This is an open access article under the CC BY-NC-ND license

(<http://creativecommons.org/licenses/by-nc-nd/4.0/>).

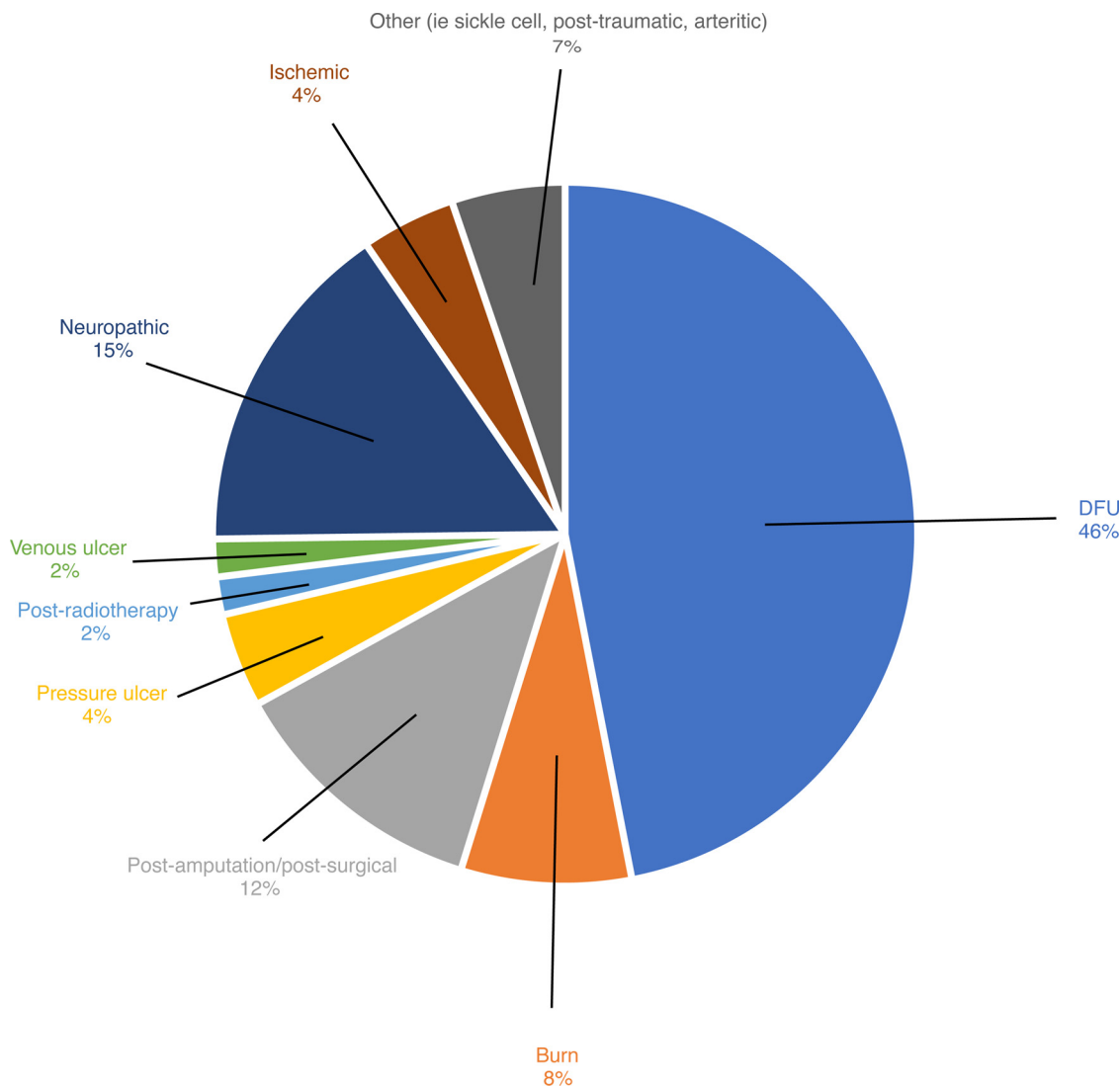


Fig. 1. Types of wounds. The cases included in this paper are categorized by type of wounds. The majority of the cases were DFUs (46 %), followed by neuropathic ulcers (15 %), post amputation/post surgical wounds (12 %), burns (8 %), other types of wounds such as post-traumatic or sickle cell (7 %), pressure and ischemic ulcers (4 %) and venous and post-radiotherapy ulcers (2 %).

CACIPLIQ20[®], to full wound closure. CACIPLIQ20[®] is a bioengineered structural analogue of heparan sulfate (HS) glycosaminoglycans, called ReGeneraTing Agents (RGTA). This technology is an innovative, minimally invasive approach in the field of regenerative medicine that aims to promote tissue regeneration by reconstructing the cellular micro-environment following tissue injury [6]. HS are degraded at the site of a lesion, resulting in a disorganized extracellular matrix and destroyed tissue. RGTAs replace damaged HS and restore the extracellular matrix architecture, which is vital for cell communication, protection of heparin binding growth factors, cytokines and chemokines from proteolysis and thereby facilitate the process of tissue repair and regeneration.

Here, we analyzed the rate of healing of a matrix therapy agent, CACIPLIQ20[®], for the treatment of 119 patients with non-healing wounds of various etiologies. All were treated with CACIPLIQ20[®] by secondary intention and all were given treatment as outpatients in wound care centers or hospitals after all other treatment options had failed, many facing a high risk for amputation.

2. Patients and methods

Of the ~500,000 patients treated with CACIPLIQ20[®] over the past 10 years world-wide, we selected the cases with total wound closure at

the end of the treatment, for which we could collect the maximum amount of information to perform the analyses in this study ($n = 119$). Although many of the cases that were not selected showed clear improvement throughout the treatment, either the treatment was stopped for various reasons (not due to the treatment itself) and thus the patient did not achieve wound closure, or we did not have access to adequate information regarding the patient and the wound (we were not able to retrieve thorough documentation from the health care practitioners who treated the patient).

The primary outcome of this analysis was to determine how many days it would take to close a non-healing wound using CACIPLIQ20[®] treatment. Therefore, only patients who achieved total wound closure by the end of CACIPLIQ20[®] treatment were included. The secondary outcome was to determine whether wound age affected the healing rate, more specifically, whether there is a difference in healing rate between wounds of less than 6 months (but more than 4) and those present for more than 6 months. Patients were included from both published studies and un-published cases. For each patient, age, sex, wound type, wound location, time to closure and treatment photos were collected, when possible. Informed consent was obtained from each patient.

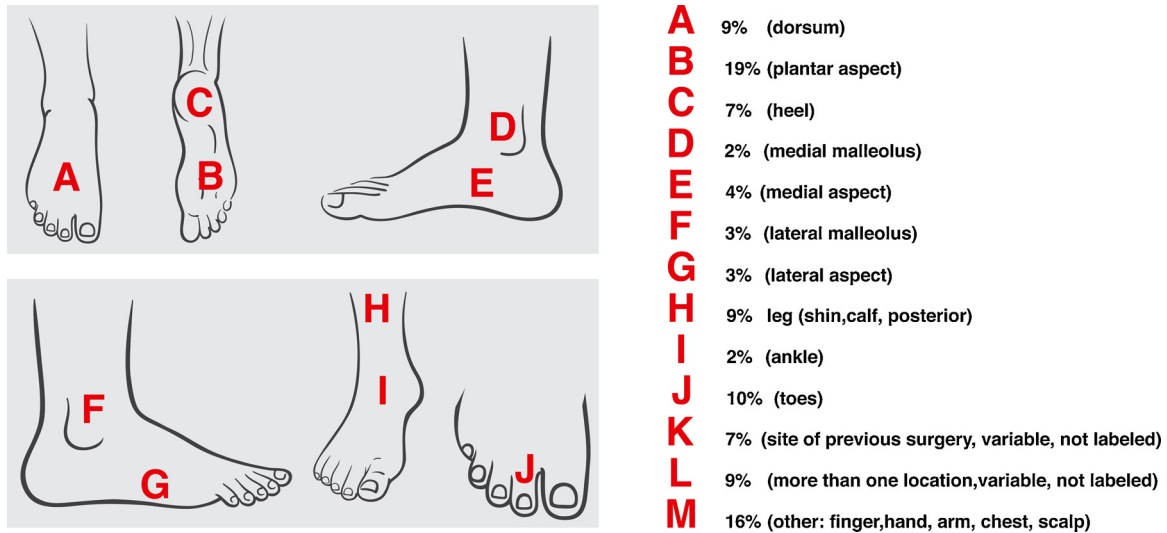


Fig. 2. Location of wounds on feet/legs. Most of the wounds on the feet/legs were located on the plantar aspect (19 %), followed by the toes (10 %), dorsum (9 %), leg (9 %), heel (7 %), medial aspect (4 %), lateral malleolus (3 %), lateral aspect (3 %), ankle (2 %) and medial malleolus (2 %). Nine percent presented wounds in more than one location. Seven percent were located on sites of previous surgery. Sixteen percent of cases were found on other parts of the body such as the fingers, hand, arm, chest and scalp.

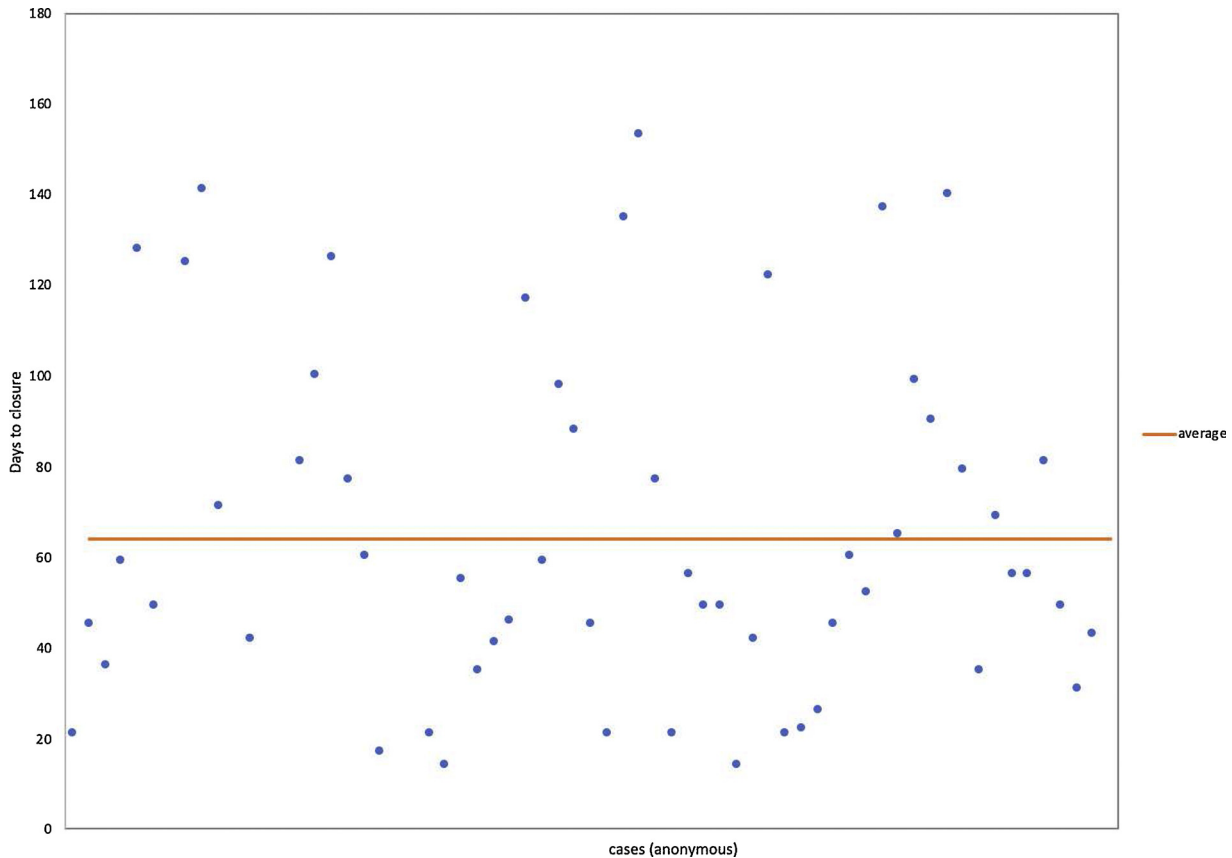


Fig. 3. Time to complete closure of all cases. The time to complete wound closure using CACIPLIQ20® for all cases was an average of 64 days.

2.1. Patient selection

Of the 50,000 patients treated with CACIPLIQ20® over the past 10 years world-wide, we selected the cases with total wound closure at the end of the treatment, for which we could collect the maximum amount of information to perform the analyses in this study (n = 119). Although many of the cases that were not selected showed clear improvement throughout the treatment, either the treatment was stopped

for various reasons (not due to the treatment itself) and thus the patient did not achieve wound closure, or we did not have access to adequate information regarding the patient and the wound (we were not able to retrieve thorough documentation from the health care practitioners who treated the patient). The primary outcome of this analysis was to determine how many days it would take to close a non-healing wound using CACIPLIQ20® treatment. Therefore, only patients who achieved total wound closure by the end of CACIPLIQ20® treatment were

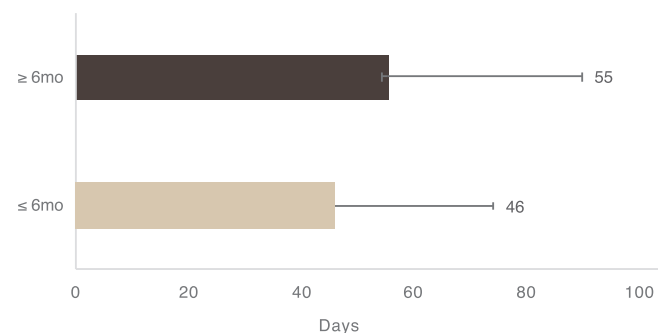


Fig. 4. Time to closure of wounds aged less than 6 months versus greater than 6 months. No significant difference was found for time to wound closure between wounds aged less than 6 months (46 days) and wounds aged more than 6 months (55 days) ; un-paired *t*-test *p* value, *p* = 0.1956.

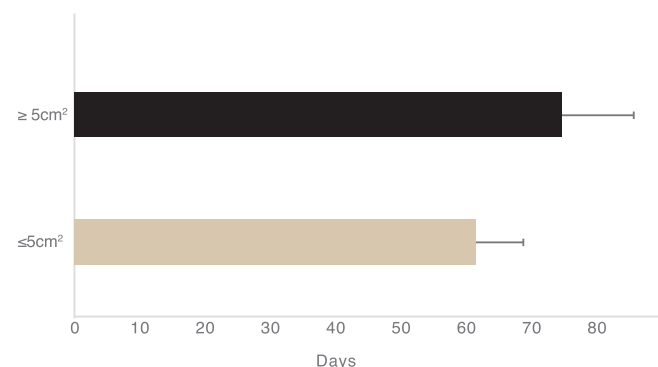


Fig. 5. Time to wound closure of wounds with area less than 5 cm² versus area greater than 5 cm². There was no significant difference found for the time to wound closure between wounds less than 5 cm² (61 days) and wounds ≥ 5 cm² (72 days) ; un-paired *t*-test *p* value, *p* = 0.4172.

included. The secondary outcome was to determine whether wound age affected the healing rate, more specifically, whether there is a difference in healing rate between wounds of less than 6 months (but more than 4) and those present for more than 6 months. Patients were included from both published studies and un-published cases. For each patient, age, sex, wound type, wound location, time to closure and treatment photos were collected, when possible. Informed consent was obtained from each patient.

2.2. Cost-effectiveness

Cost-effectiveness was evaluated based on the initial wound size area recorded for each patient; it was assumed that wound healing was linear until wound closure. Given that one spritz of the CACIPLIQ20® spray solution delivers 140ul and can cover ~8mm² of the wound (200 euros/172 GBP per bottle), we were able to estimate the total amount of product (number of spritzes) used for each patient and compared this to the cost of CACIPLIQ20® in its original vial format (1 week treatment of 2 applications, 5 ml vials costing 200 euros/172 GBP each for 25cm² wound area), a mode of delivery that is not always compatible with wound size and generates over 99 % waste of product.

3. Results

The 119 cases included in this study were treated in 15 different countries (Saudi Arabia, Qatar, United Arab Emirates, Morocco, Tunisia, Mexico, France, England, Netherlands, Malaysia, Czech Republic, Greece, Lebanon, USA, Philippines) and had a median age of 63 years old. Almost half of them 61 % were DFU; among them, 15 % were severe neuropathic DFUs and 12 % were post-amputation non-healing/post-surgical DFUs. The remaining non-healing cases ranged from pressure ulcers (4 %), ischemic (4 %), venous (2 %) and post-radiotherapy (2 %), as well as second intention burns (8 %). Seven percent of cases included one sickle cell disease wound, post-traumatic wounds, a bedsore and arteritic wounds (Fig. 1). Of the wounds located on/near the feet, many were on the plantar aspect (19 %) or affected more than one area of the foot (9 %). Sixteen percent of the wounds

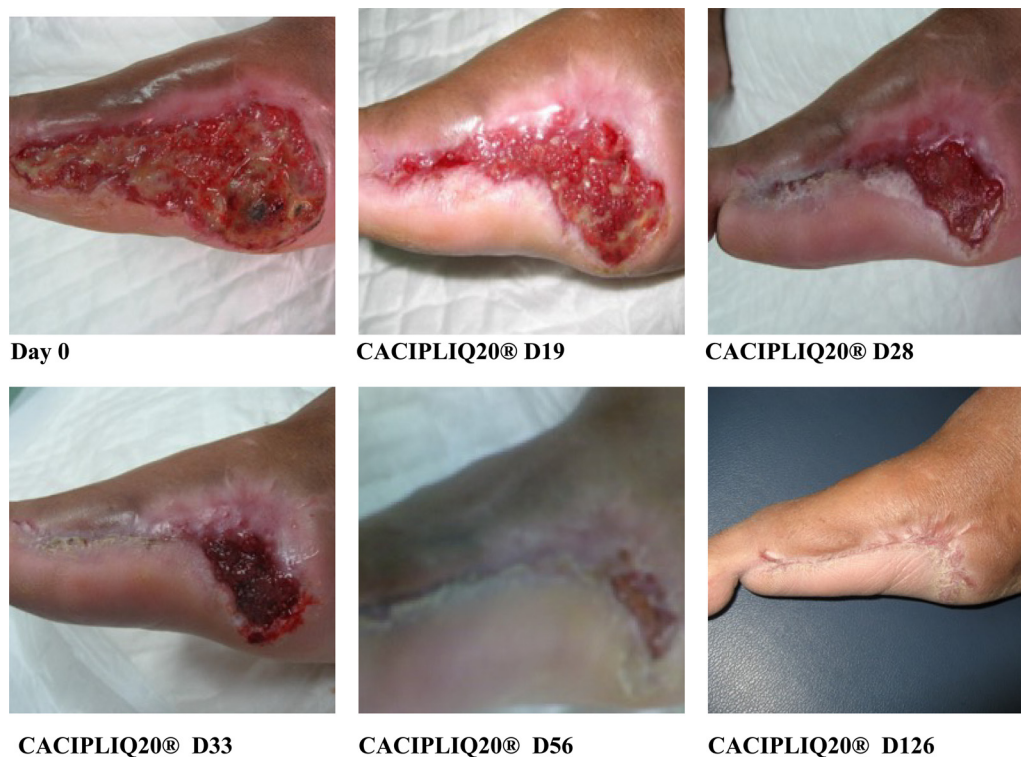

Fig. 6. Trans-metatarsal amputation. 48 year old woman with Type 2 Diabetes presented with critical limb ischemia and gangrenous toes. She underwent femoropopliteal bypass, followed by amputation of the gangrenous toes and part of the foot. She was left with a non-healing wound which was not improving with the use of various types of dressings. CACIPLIQ20® treatment was started and the wound completely healed by 126 days.

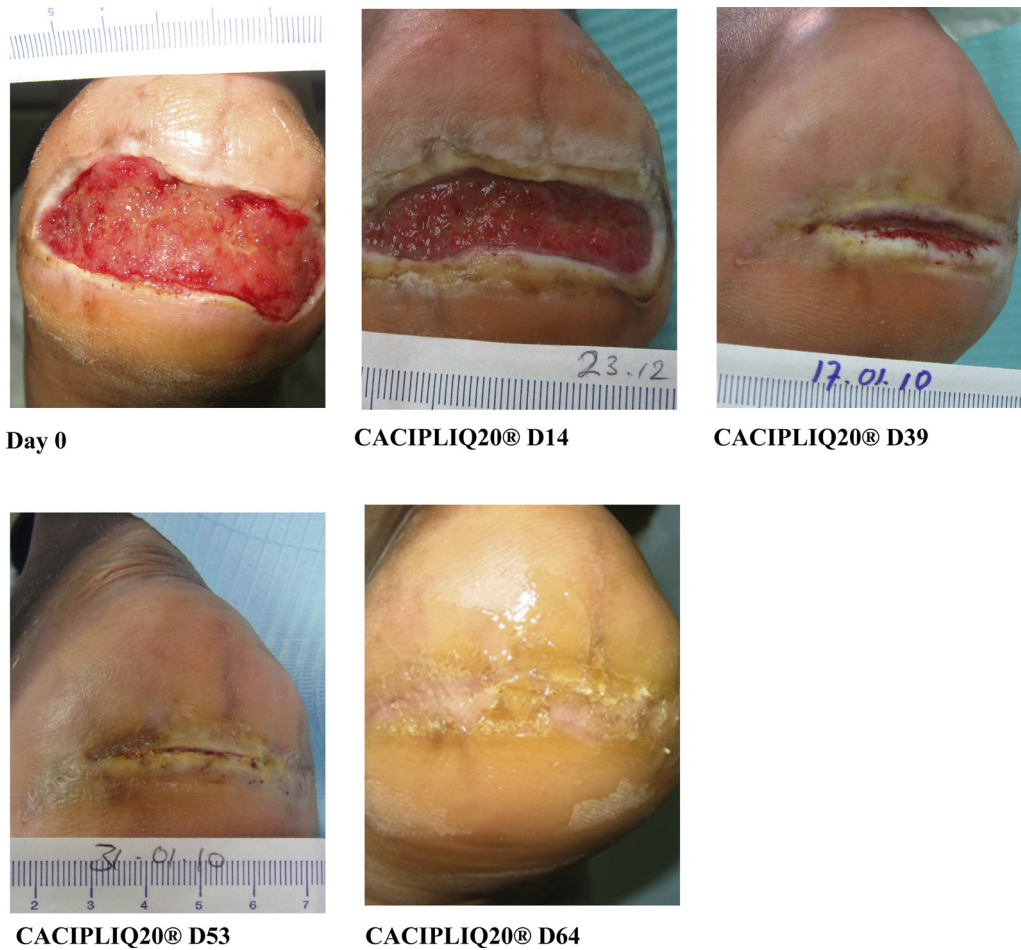

Fig. 7. Pressure Ulcer. 66 year old man with Type 2 Diabetes presented with swelling and discharge from the heel of his left foot. Debridement was performed and he was left with a non-healing wound over the posterior aspect of the heel. Various treatments resulted in no improvement for 13months. It was decided to begin treatment with CACIPLIQ20®. The wound healed with minimal scarring in 63 days.

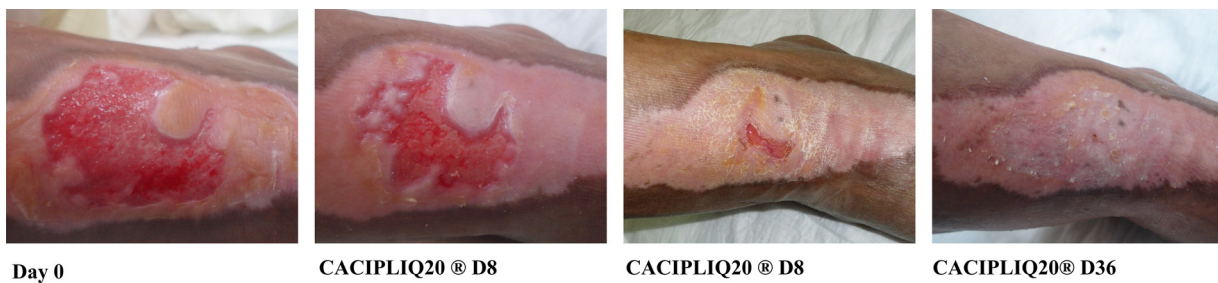


Fig. 8. Burn. 64 year old man with Type 2 Diabetes, ischemic and neuropathic arrived with a severe burn from hot water on the dorsum of his foot and ankle. No improvement of the wound was made for 1.5 months using Ag and anti-microbial dressings three times a week. CACIPLIQ20® treatment was used twice a week with complete healing achieved in 36 days.

were located on other parts of the body including the finger, hand, arm, chest or scalp (Fig. 2). The time to closure using CACIPLIQ20® for all cases was an average of 64 days (Fig. 3). Wounds of less than 6 months of age healed in 46 days and wounds lasting more than 6 months healed in 55 days, a difference which was not significant ($p = 0.1856$, Fig. 4). When examining wound size and its relation to healing rate, wounds less than 5 cm² healed in 61 days and wounds ≥ 5 cm² healed in 72 days, a difference which was not significant ($p = 0.4172$, Fig. 5).

3.1. Case illustrations

The cases we chose to photographically illustrate show in detail the wide range of wounds that were successfully treated with CACIPLIQ20®

included in this overview (Figs. 6–13). Each figure legend describes the case/s.

4. Discussion

Here, we present data for 119 patients treated with matrix therapy agent CACIPLIQ20® and show that regardless of wound size and wound age, time to wound closure remains relatively the same, around 2 months (Figs. 3–5). This was an interesting and unexpected finding which demonstrates the efficacy of CACIPLIQ20® in healing wounds of diverse etiologies, ages and sizes. We recognize the bias of only selecting cases which reached complete wound closure. However, we specifically decided to use this criterion to select the cases because our

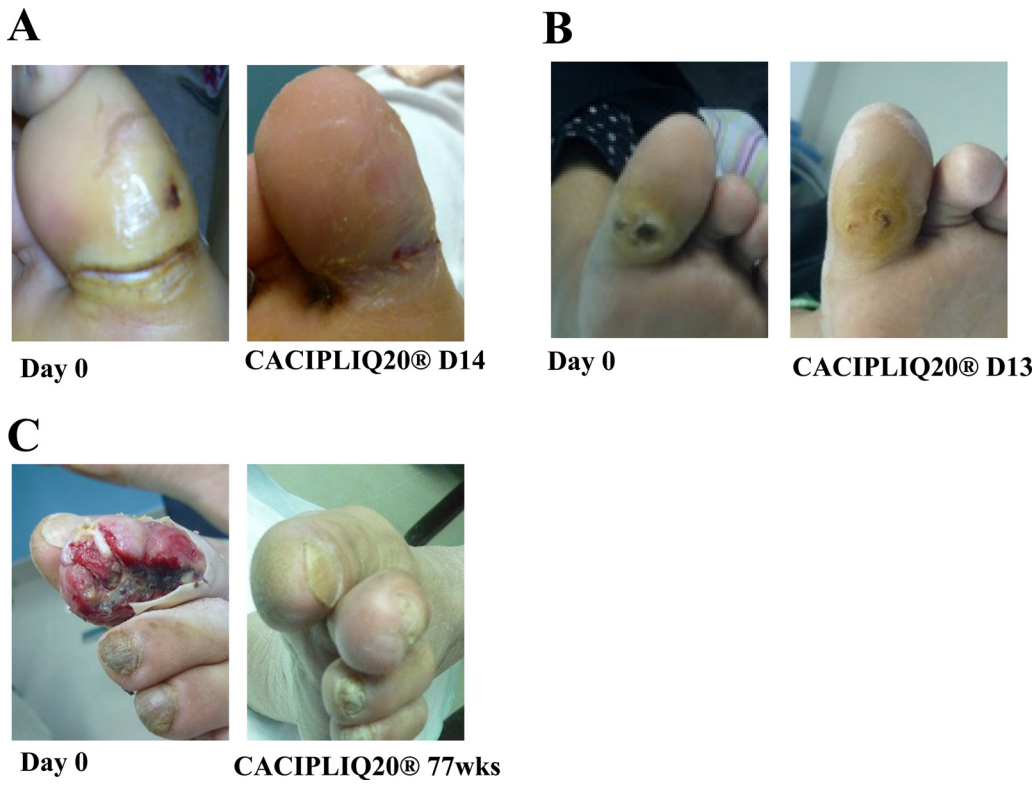


Fig. 9. Long-standing non-healing wounds under the toes. A) 67 year old woman with Type 2 Diabetes presented with a 3 year old DFU. CACIPLIQ20® treatment was started and the wound healed after 14 days. B) A 30 year old woman with Type 2 Diabetes presented with a 3 year old DFU. The wound healed in 13 days with CACIPLIQ20® treatment. C) 28 year old woman whose big toe was scheduled for amputation. Full healing was achieved with CACIPLIQ20® treatment at 17 weeks.

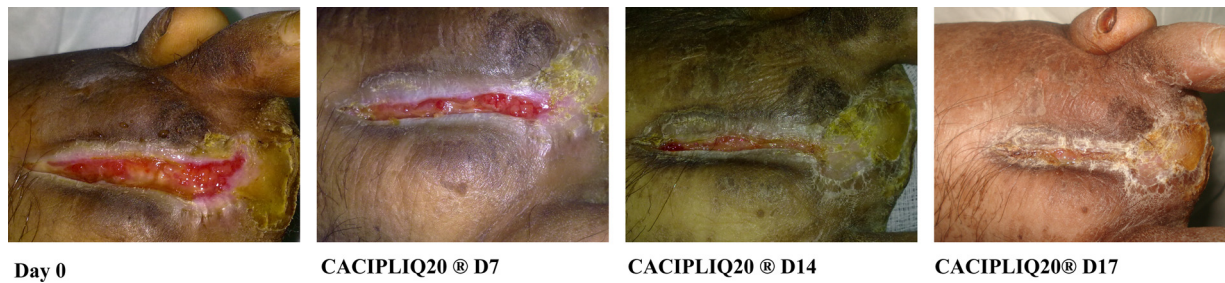


Fig. 10. DFU. Patient presented with a DFU on top of his left foot which had not shown any progress for 3 months. CACIPLIQ20® was applied and complete closure was achieved at 17 days.

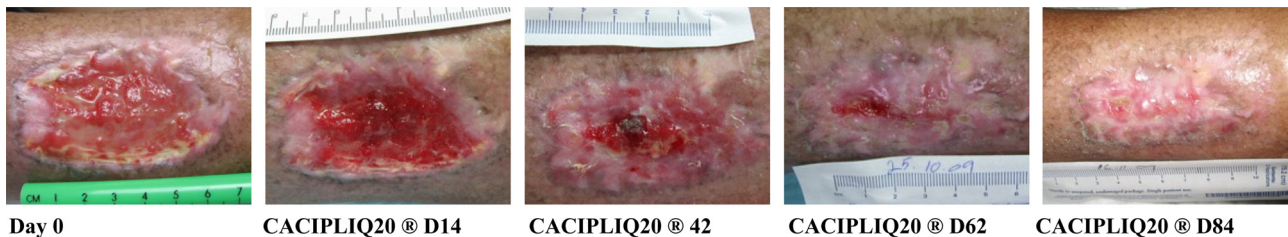
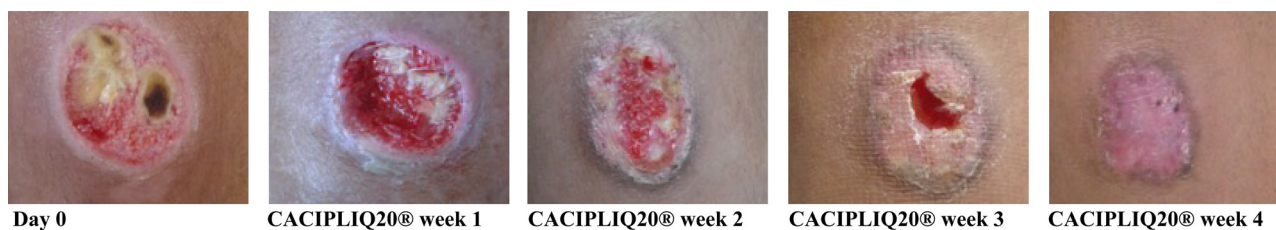
Fig. 11. Post radiation therapy. 74 year old man with Type 2 Diabetes had a malignant tumor (soft tissue sarcoma) over the lateral aspect of his leg. The tumor was removed and radiotherapy was given after the surgery. He developed a non healing ulcer, present for 1 year. Various dressings were used to no success. CACIPLIQ20® was applied and the wound healed in less than 3 months.

primary objective was to determine how many days it would take to close a non-healing wound using CACIPLIQ20® treatment. Thus, only cases with fully healed wounds were evaluated in order to assess how long complete wound healing can be achieved using this therapy. It is important to note that these cases had not shown any evidence of healing despite use of conventional treatments and most were expected to be amputated as a result of the non-healing wound.

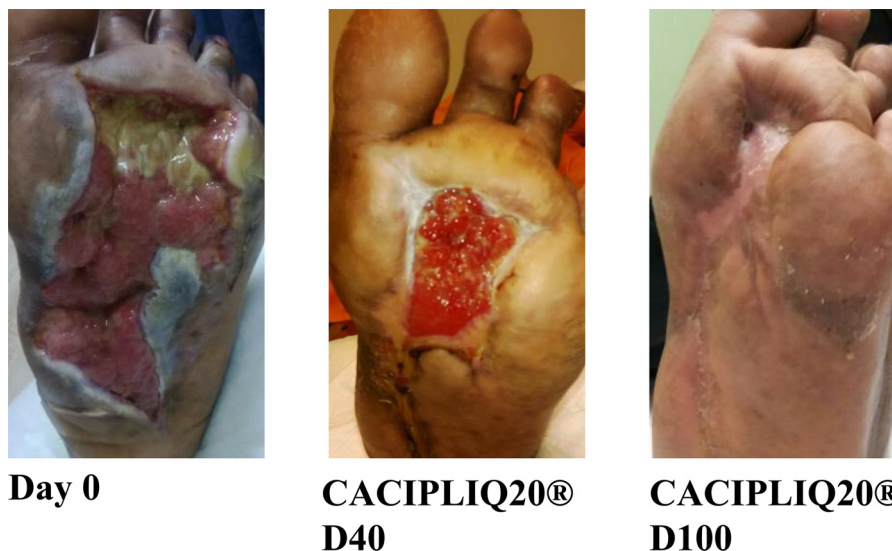It is important to mention that in order for CACIPLIQ20® to fully penetrate the wound bed and have its full effect, thorough extensive debridement must be performed prior to application. More specifically,

fibrin must be removed, since fibrinogen binds heparin via numerous binding sites and would therefore bind CACIPLIQ20®. Not only is debridement a crucial step required to ensure CACIPLIQ20®'s efficiency, but it is the biggest limiting factor in the success of CACIPLIQ20® in certain countries. For example, the biggest market for CACIPLIQ20® has been and is currently in the Gulf countries, since the majority of patients are treated in wound care centers or hospitals, where their wounds are systematically debrided. However, in European countries where patients are mostly treated at home or in private practice, debridement is not properly performed. Thus, CACIPLIQ20®



Day 0 CACIPLIQ20® week 1 CACIPLIQ20® week 2 CACIPLIQ20® week 3 CACIPLIQ20® week 4

Fig. 12. DFU. 20 year old man with T1 Diabetes presented with a DFU of 4 weeks on the anterior aspect of his leg. CACIPLIQ20® was applied and the wound healed in 4 weeks.



Day 0

CACIPLIQ20®
D40

CACIPLIQ20®
D100

Fig. 13. DFU. A 51 year old man presented with a DFU on the plantar aspect, which had not progressed for 8 months. After thorough debridement, CACIPLIQ20® was applied and the wound healed in 100 days.

does not adequately penetrate the wound bed and does not produce its expected results.

At the time that these cases were treated, CACIPLIQ20® was available in a vial format and applied by soaking a gauze pad with the solution and applying it to the wound, resulting in a lot of waste (kit of two 5 ml vials, 220cm² gauze pad, 200 euros/week or a kit of three 1.5 ml vials, 35cm² gauze pad, 100 euros for 10 days or 3 treatments). Since these cases were treated, a spray format of the same CACIPLIQ20® solution was developed, making the product much more economical and user-friendly. For example, it would have costed an average total of 74 euros to treat these cases measuring an average area of 14 cm² (less than one bottle) to wound closure using the spray format, versus 600 euros using the vial format. Moreover, cost savings are achieved by using CACIPLIQ20® since it was able to heal a wound to full closure in about 60 days, regardless of its initial size or age. The possibility of faster and complete closure also reduces the rate of complications such as infections, hospitalization and amputation [7]. Thus, overall cost savings can be achieved through faster healing rates and reduced incidence of infection and amputation, in addition to reduced costs linked to less time/care required from health care practitioners. Importantly, in addition to decreasing treatment costs, faster complete wound closure also relieves the physical and emotional burden of non-healing chronic wounds, consequently improving the patient's prognosis and quality of life.

Patients with chronic wounds often suffer from severe pain and it is one of the main contributors to decreased quality of life. It is worth mentioning the pain-relieving effects of CACIPLIQ20® related to wound healing. In a study by Groah et al. [8], wound-related pain was measured via the wound pain scale (WPS) and the Visual and Analogue Pain Scale (VAPS) and showed a profound reduction in pain (5.12 to 1.78 WPS and 2.78 to 1.11 VAPS); Desgranges et al. [9] also noted that the

patients also experienced striking pain relief as a direct consequence of healing. Although this effect was not quantified, it was clearly expressed by all of the patients. Pain relief and reduced sensitivity were also noted in a case series of post-amputation and severe wounds of the hands treated with CACIPLIQ20® [10].

Most likely as a consequence of decreased wound pain related to faster healing, patients in the Desgranges case series also decreased consumption of analgesics and the remaining patients who continued use went from taking class 3 and 2 analgesics to class 1 analgesics [9]. Pain relief was also reported by all of the patients included in the study by Slim et al. [11]. This effect has also been experienced by patients treated with RGTA matrix therapy for corneal ulcers, with the VAS pain score decreasing from 72/100 at baseline to 50/100 after one week and down to 29/100 after four weeks of treatment, $p < 0.001$ [12].

The cases described in this report illustrate complete wound closure for very difficult, chronic cases where CACIPLIQ treatment was considered as a last attempt for healing. CACIPLIQ offers a unique, cost-effective solution with a user-friendly spray delivery system. The mode of action is supported by robust preclinical studies and reflects this clinical success, assuming the extracellular matrix is properly accessible after thorough debridement. After almost 10 years of use and over 50,000 treated cases, no adverse events have been reported.

Looking back on 10 years of use, CACIPLIQ20® has shown to be an effective therapeutic option for patients with chronic, hard to heal wounds with healing time to complete closure of about 2 months. In conclusion, CACIPLIQ20® can be considered as an effective treatment for chronic wounds, can provide major improvement of quality of life through rapid and complete healing and has the added benefit of being cost-effective.

Funding

This research did not receive any specific grant from funding agencies in the public, commercial, or not-for-profit sectors.

Ethical statement

Informed consent was obtained from each patient for the use of all data including photos.

Financial disclosure

This work done for this paper did not receive any specific grant from funding agencies in the public, commercial, or not-for-profit sectors.

Denis Barritault is the inventor of the patented RGTA® technology used in this study and has financial interest.

Declaration of Competing Interest

DB is the inventor of the patented RGTA® technology used in this study and has financial interest.

Acknowledgment

Author wish to thank Dr Al Malaq (KSFH Ryad, KSA), S. Al Harby (KFSH Buraidah, Dr S. El Hoseny (Dubai, UAE), Pr P.Desgranges (CHUHM, Creteil,Fr),Dr SI.Slim (Sousse TUN).

References

[1] G. Han, R. Ceilley, Chronic wound healing: a review of current management and

treatment, *Adv. Ther.* 34 (3) (2017) 599–610, <https://doi.org/10.1007/s12325-017-0478-y>.

- [2] M. Narres, T. Kvitkina, H. Claessen, S. Droste, B. Schuster, S. Morbach, G. Rümenapf, K. Van Acker, A. Icks, Incidence of lower extremity amputations in the diabetic compared with the non-diabetic population: a systematic review, *PLoS One* 12 (8) (2017) 1–28, <https://doi.org/10.1371/journal.pone.0182081>.
- [3] World Health Organization, WHO Global Report on Diabetes, (2016).
- [4] C.K. Sen, G.M. Gordillo, S. Roy, R. Kirsner, L. Lambert, T.K. Hunt, F. Gottrup, G.C. Gurtner, M.T. Longaker, Human skin wounds: a major and snowballing threat to public health and the economy, *Wound Repair Regen.* 17 (2009) 763–771, <https://doi.org/10.1111/j.1524-475X.2009.00543.x>.
- [5] J. Posnett, F. Gottrup, H. Lundgren, G. Saal, The resource impact of wounds on health-care providers in Europe, *J. Wound Care* 18 (4) (2009) 154–161, <https://doi.org/10.12968/jowc.2009.18.4.41607>.
- [6] D. Barritault, M. Gilbert-Sirieix, K. Rice, F. Siñeriz, D. Papy-Garcia, C. Baudouin, P. Desgranges, G. Zakine, J.L. Saffar, J. van Neck, RGTA(R) or ReGeneraTing agents mimic heparan sulfate in regenerative medicine: from concept to curing patients, *Glycoconj. J.* 34 (3) (2016) 325–338, <https://doi.org/10.1007/s10719-016-9744-5>.
- [7] A. Langer, W. Rogowski, Systematic review of economic evaluations of human cell derived wound care products for the treatment of venous leg and diabetic foot ulcers, *BMC Health Serv. Res.* 9 (2009) 115, <https://doi.org/10.1186/1472-6963-9-115>.
- [8] S.L. Groah, A. Libin, M. Spungen, K.L. Nguyen, E. Woods, M. Nabil, J. Ramella-Roman, D. Barritault, Regenerating matrix-based therapy for chronic wound healing: a prospective within-subject pilot study, *Int. Wound J.* 1 (2011) 85–95, <https://doi.org/10.1111/j.1742-481X.2010.00748.x>.
- [9] P. Desgranges, T. Louissaint, E. Allaire, B. Godeau, K. Kichenin, J.P. Becquemin, D. Barritault, First clinical pilot study on critical ischemic leg ulcers with matrix therapy regenerating agent (RGTA®) technology, *J. Wound Tech.* 13 (2011) 2–6.
- [10] S.A. Roohi, D. Barritault, ReGeneraTing Agents (RGTA®) are a new option to improve amputation outcomes in the recovery of severe hand injuries, *Clin. Case Rep.* (2018) 1–9, <https://doi.org/10.1002/ccr3.1797>.
- [11] I. Slim, H. Tajouri, D. Barritault, M. Kacem Njah, K. Ach, M. Chadli Chaieb, L. Chaieb, Matrix protection therapy in diabetic foot ulcers: pilot study of CACIPLIQ20, *J. Wound Tech.* 17 (2012) 16–20.
- [12] C.K. Chebbi, K. Kichenin, N. Amar, H. Nourry, J.M. Warnet, D. Barritault, C. Baudouin, Pilot study of a new matrix therapy agent (RGTA OTR4120) in treatment-resistant corneal ulcers and corneal dystrophy, *J. Fr. Ophtalmol.* 31 (5) (2008) 465–467, [https://doi.org/10.1016/s0181-5512\(08\)72462-8](https://doi.org/10.1016/s0181-5512(08)72462-8).